

Parasagittal Meningioma in a Middle-aged Female Harbours Metastatic Ductal Carcinoma: A Rare Case of Incidentally Detected Tumour-to-tumour Metastasis

NADIA SHIRAZI¹, SANJEEV PANDEY², MEENA HARSH³, SIDDHARTHA TYAGI⁴

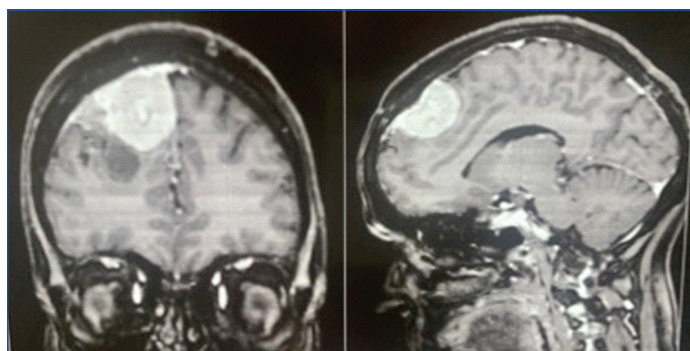ABSTRACT

Metastasis of a tumour particularly coming from breast into an intracranial meningioma is a rare phenomenon. Several factors related to tumour microenvironment have been suggested in the pathophysiology of these lesions, particularly the rich vascular network of meningiomas, expression of common hormonal receptors like Oestrogen Receptor (ER) and Progesterone Receptor (PR), local immunosuppression, and presence of cell adhesion molecules. Here, we present a clinicoradiologically unsuspecting case of intracranial, parasagittal meningioma who was operated for relief of symptoms of mass effect and was incidentally detected with tumour metastasis within the meningioma. A 50-year-old female presented with seizures, headache and visual disturbances since last one month. Radiology revealed a parasagittal mass which was likely to be meningioma. The patient was operated. On histopathology, a low-grade meningioma was seen with areas of metastatic adenocarcinoma. The metastatic foci were surrounded by fibroblastic meningioma cells. On Immunohistochemistry (IHC), the metastatic tumour cells were strongly positive for PR and Cytokeratin 7 (CK7) and a diagnosis of fibroblastic meningioma with intratumoural metastasis of ductal carcinoma was rendered. The patient was given radiotherapy for brain tumour and also started on chemotherapy for breast carcinoma with brain metastasis. Since the entity of "Tumour-to-tumour Metastasis (TTM)" is uncommonly thought of and its detection is not easy, it is important that both clinicians and pathologists should adequately examine tissue samples of excised meningioma, as detecting the presence of any metastatic foci within the main mass will alter the prognosis and treatment plan considerably.

Keywords: Breast carcinoma, Chemotherapy, Hormonal receptors, Immunohistochemistry, Intracranial, Occult

CASE REPORT

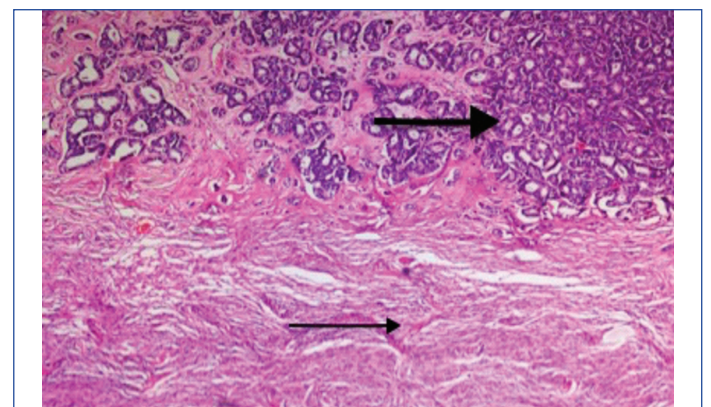
A 50-year-old female presented with multiple episodes of generalised tonic clonic seizures since one month. She also complained of headache and blurring of vision since 20 days. On examination-Glasgow Coma Scale (GCS) score was 15/15. Magnetic Resonance Imaging (MRI) brain, which showed a right anterior 1/3rd parasagittal extra axial mass favouring meningioma [Table/Fig-1]. The patient was taken up for surgery and a right frontal craniotomy was performed with total excision of tumour.



[Table/Fig-1]: Contrast Enhanced Computed Tomography (CECT) showing a parasagittal dural-based mass.

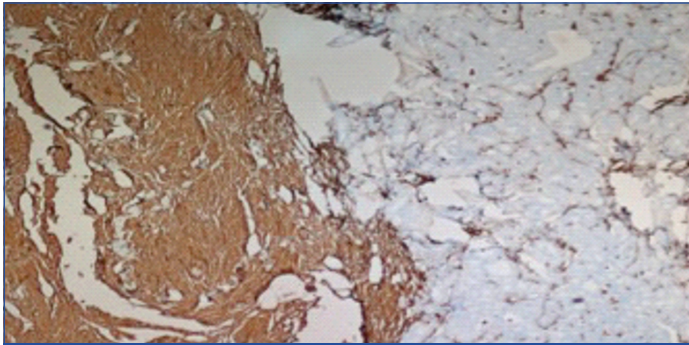
Intraoperative findings revealed a firm, moderately vascular tumour which had good plane with normal brain. The tumour appeared to be arising from convexity dura and falx and invading superior sagittal sinus. Postoperative GCS score was E4V5M6. The tissue was sent for histopathological examination, using Haematoxylin and Eosin (H&E). Grossly, there were multiple greyish white fragmented soft to firm tissue pieces together measuring 5×3.2×1.2 cm. Microscopic examination showed two distinct

areas. There was marked proliferation of atypical glandular tissue with formation of few papillae and complex cribriform pattern. Cells had round to pleomorphic nuclei with coarse chromatin and inconspicuous nucleoli. Mitotic figures were 1-2/ High Power Field (HPF). Psammoma bodies were seen and necrosis was present. This atypical glandular proliferation was closely seen abutting a fibroblastic meningioma as well as focally infiltrating it. The meningothelial cells were bland looking with plump to oval nuclei and finely granular chromatin. Mitotic figures were sparse. A diagnosis of fibroblastic World Health Organisation (WHO) grade 1 meningioma with metastatic adenocarcinoma was rendered [Table/Fig-2]. Immunohistochemistry (IHC) was performed for diagnosis of probable primary. Tumour cells were positive for Vimentin, Epithelial Membrane Antigen (EMA), Cytokeratin 7 (CK7), Progesterone Receptor (PR) and negative for CK20 and Glial Fibrillary Acidic Protein (GFAP) [Table/Fig-3,4]. Ki67 (mitotic index) expression was

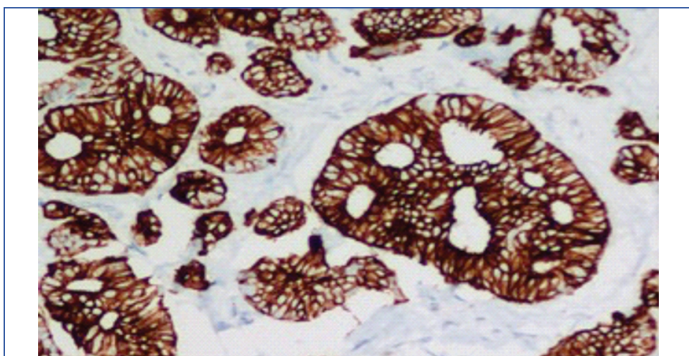


[Table/Fig-2]: Syncytial pattern of meningothelial cells (thin arrow) surrounding metastatic adenocarcinoma (thick arrow) (H&E X10).

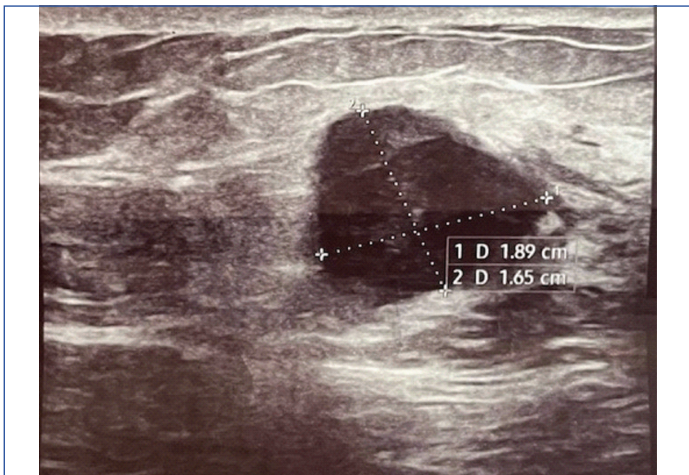
>40% in metastatic tumour areas while it was <5% in meningioma. Ductal carcinoma breast was postulated as primary on basis of IHC findings (CK7, EMA PR positive). Mammography showed mixed echogenicity and microcalcification in the right breast upper outer quadrant, suggestive of breast malignancy [Table/Fig-5]. The patient was sent for radiotherapy of brain tumour bed along with chemotherapy for metastatic breast carcinoma.



[Table/Fig-3]: Meningioma expressing strong Vimentin positivity whereas metastatic ductal carcinoma is negative using IHC (X20).



[Table/Fig-4]: CK7 positivity in metastatic carcinoma using IHC (X40).



[Table/Fig-5]: Mammogram right breast showing lump with mixed echogenicity and microcalcification.

DISCUSSION

Around one in 35 cancer patients may be affected by another primary tumour [1]. An extracranial malignant neoplasm metastasising to an intracranial tumour is very unusual and can be described as Tumour-to-tumour Metastasis (TTM) [2]. TTM is a rare phenomenon and is distinct from collision tumours/lesions.

Collision lesions refer to certain vascular, tumourous (benign or malignant), congenital, inflammatory or infectious conditions which are histologically distinct from each other and can be found in varying proportions within a mass. While the describing features of TTM should show that metastatic tumour deposits must at least be partially surrounded by benign tumour tissue with a specific histology, and the evidence of a primary tumour elsewhere must be proved clinicoradiologically [3].

TTM was first described by Berent W as early as in 1902 [4]. The terms "TTM" and "collision tumour" have often been used interchangeably. Two neoplasms in vicinity that invade one another are called collision tumours, however, TTM is more difficult to define. To differentiate between these two lesions, four criteria were outlined by Campbell LV et al., in 1968: 1) there should be co-existence of at least two primary tumours; 2) the host tumour must be a true neoplasm; 3) the metastatic focus must be able to demonstrate growth within the tumour and should not be present as a result of contiguous growth, lymphovascular emboli or a collision process; and 4) a leukaemia or lymphoma within a lymph node as a host tissue cannot be considered for TTM [5].

Although any tumour can be a recipient, but meningiomas have been implicated as the most common intracranial neoplasm to harbour metastasis [6]. The donor neoplasm is most frequently lung or breast carcinoma, while rare cases of metastasis from other primary tumours have also been reported [7,8]. Petraki C et al., have reported carcinoma of the cervix metastasising to renal cell carcinoma and urothelial carcinoma of bladder metastasising to solitary fibrous tumour of pleura [9]. Ricketts R et al., have described pancreatic neuroendocrine carcinoma metastasising to renal angiomyolipoma [10]. However, not many cases have described intratumoural metastasis within a meningioma as in the present case.

Manini C et al., stated that the recipient in a case of TTM is almost always a cytologically benign tumour like a meningioma, lipoma, Warthin tumour, Schwannoma or a low-grade carcinoma like grade I clear cell renal cell carcinoma, papillary thyroid carcinoma, pheochromocytoma, well differentiated pancreatic neuroendocrine tumour etc., [11]. This might be explained by that these tumours are hypervascularised and non-necrotic, so new settlements are preferred at these sites.

Meningiomas are known to be having special features that promote tumour growth, such as hypervascularity, slow growth rate, high lipid, and collagen content. These tumours tend to strongly express ER (9%) and PR (83%), besides overexpression of cell adhesion molecule E-cadherin [12]. This sufficiently explains the high incidence of breast carcinoma metastasising within a meningioma. This process of TTM is more often seen in 5th-7th decade and can be accelerated during pregnancy [13]. Watanabe T et al., suggested that sudden appearance of symptoms, inhomogeneous enhancement and perifocal oedema of meningioma is a warning sign of intratumoural metastasis from systemic cancers [14]. The present case also showed mass effect symptoms like headache and blurring of vision developing over a short period of less than a month. Neurological involvement manifests later in the course of disease and is indicative of a grim prognosis.

Radiology in such cases is usually not very rewarding. It gives evidence of tumour size, perilesional oedema, margin irregularity and mushroom-like growth pattern, however, doesn't usually commit on TTM [15]. The MRI findings in the present case were also non specific and there was no suspicion of presence of a dual lesion, although CT scan in some patients has revealed hypodense areas within well demarcated, enhancing hyperdense lesions. Histopathology, thus remains the gold standard for giving a diagnosis.

Management of TTM should include surgical removal of the tumour with postoperative adjuvant therapy. Surgical removal of the tumour is necessary to minimise spread of metastatic tumour, decrease mass effect caused by tumour, and also to give a histopathological diagnosis.

CONCLUSION(S)

Meningioma constitutes 20% of intracranial tumours and has microenvironment favourable to receive metastasis from elsewhere. Clinicians as well as pathologists should carefully assess all

meningioma cases with a possibility of finding an intratumoural occult malignancy as this will alter treatment plan and prognosis considerably.

REFERENCES

- [1] Moertel CG. Incidence and significance of multiple primary malignant neoplasms. *Ann N Y Acad Sci.* 1964;114(2):886-95.
- [2] Moody P, Murtagh K, Piduru S, Brem S, Murtagh R, Rojani AM. Tumor-to-tumor metastasis: pathology and neuroimaging considerations. *Int J Clin Exp Pathol.* 2012;5(4):367-73.
- [3] Pisapia DJ. Pathology of Brain Metastases. In: Ramakrishna R, Magge R, Baaj A, Knisely J. (eds). *Central Nervous System Metastases.* Chambridge: Springer; 2020: pp 53-67. Doi: 10.1007/978-3-030-42958-4.
- [4] Berent W. Seltene metastasenbildung. *Zentralbl Allg Pathol.* 1902;13:406-10.
- [5] Campbell LV Jr, Gilbert E, Chamberlain CR Jr, Watne AL. Metastases of cancer to cancer. *Cancer.* 1968;22(3):635-43. Available from: [https://doi.org/10.1002/1097-0142\(196809\)22:3<635::AID-CNCR2820220320>3.0.CO;2-O](https://doi.org/10.1002/1097-0142(196809)22:3<635::AID-CNCR2820220320>3.0.CO;2-O).
- [6] Papadakis BK, Vorrias E, Bräutigam K, Chochlidakis N, Koutsopoulos A, Mavroudis D, et al. Intrameningioma metastasis: A case-based literature review. *J Clin Neurosci.* 2021;93:168-73.
- [7] Han HS, Kim EY, Han JY, Kim YB, Hwang TS, Chu YC. Metastatic renal cell carcinoma in a meningioma: A case report. *J Korean Med Sci.* 2000;15(5):593-97.
- [8] Bhargava P, McGrail KM, Manz HJ, Baidas S. Lung carcinoma presenting as metastasis to intracranial meningioma: Case report and review of the literature. *Am J Clin Oncol.* 1999;22(2):199-202.
- [9] Petraki C, Vaslamatzis M, Argyrakos T, Petraki K, Strataki M, Alexopoulos C, et al. Tumour to tumor metastasis: Report of two cases and review of the literature. *Int J Surg Pathol.* 2003;11(2):127-35.
- [10] Ricketts R, Tamboli P, Czerniak B, Guo CC. Tumor-to-tumor metastasis: Report of 2 cases of metastatic carcinoma to angiomyolipoma of the kidney. *Arch Pathol Lab Med.* 2008;132(6):1016-20.
- [11] Manini C, Provenza C, Andrés L, Imaz I, Guarch R, Nunziata R, et al. Tumor-to-tumor metastases involving clear cell renal cell carcinomas: A diagnostic challenge for pathologists needing clinical correlation. *Clin Pract.* 2023;13(1):288-96.
- [12] Hsu DW, Efid JT, Hedley-Whyte ET. Progesterone and estrogen receptors in meningiomas: Prognostic considerations. *J Neurosurg.* 1997;86(1):113-20.
- [13] Shimada S, Ishizawa K, Hirose T. Expression of E-cadherin and catenins in meningioma: Ubiquitous expression and its irrelevance to malignancy. *Pathol Int.* 2005;55(1):01-07.
- [14] Watanabe T, Fujisawa H, Hasegawa M, Arakawa Y, Yamashita J, Ueda F, et al. Metastasis of breast cancer to intracranial meningioma: Case report. *Am J Clin Oncol.* 2002;25(4):414-17.
- [15] Nayaka M, Ichimura S, Kurebayashi Y, Mochizuki Y, Fukaya R, Fukuchi M, et al. Contiguous metastasis of pulmonary adenocarcinoma to meningioma. *J Neurol Surg A Cent Eur Neurosurg.* 2019;80(2):127-30.

PARTICULARS OF CONTRIBUTORS:

1. Professor, Department of Pathology, Himalayan Institute of Medical Sciences, Dehradun, Uttarakhand, India.
2. Associate Professor, Department of Neurosurgery, Himalayan Institute of Medical Sciences, Dehradun, Uttarakhand, India.
3. Professor, Department of Pathology, Himalayan Institute of Medical Sciences, Dehradun, Uttarakhand, India.
4. Junior Resident, Department of Pathology, Himalayan Institute of Medical Sciences, Dehradun, Uttarakhand, India.

NAME, ADDRESS, E-MAIL ID OF THE CORRESPONDING AUTHOR:

Dr. Nadia Shirazi,
Professor, Department of Pathology, Himalayan Institute of Medical Sciences,
Dehradun-248140, Uttarakhand, India.
E-mail: shirazinadia@gmail.com

PLAGIARISM CHECKING METHODS: [Jain H et al.]

- Plagiarism X-checker: Nov 14, 2023
- Manual Googling: Dec 13, 2023
- iThenticate Software: Feb 19, 2024 (5%)

ETYMOLOGY: Author Origin

EMENDATIONS: 6

AUTHOR DECLARATION:

- Financial or Other Competing Interests: None
- Was informed consent obtained from the subjects involved in the study? Yes
- For any images presented appropriate consent has been obtained from the subjects. Yes

Date of Submission: **Nov 10, 2023**

Date of Peer Review: **Dec 05, 2023**

Date of Acceptance: **Feb 22, 2024**

Date of Publishing: **Apr 01, 2024**